



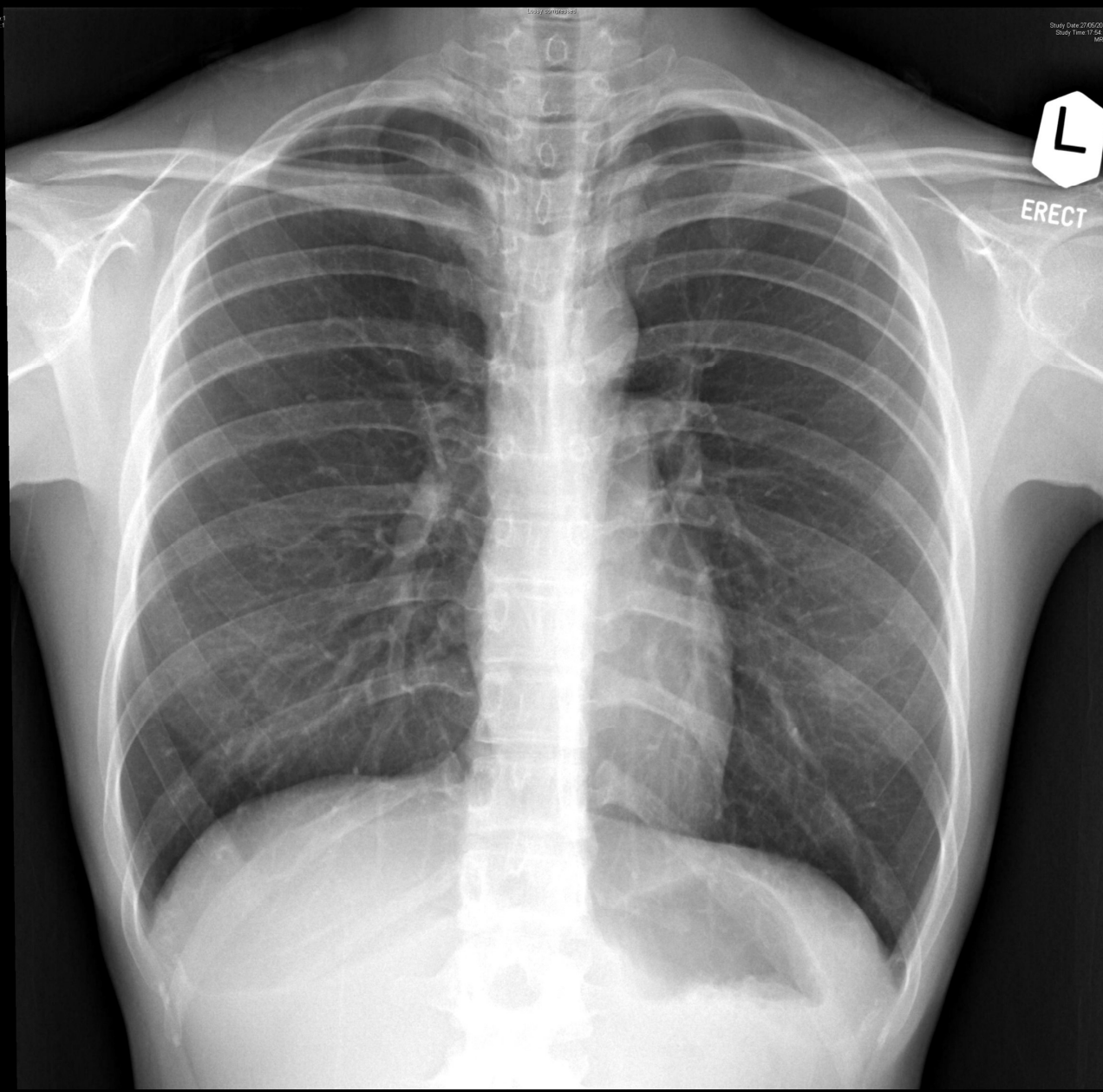
JCM OSCE

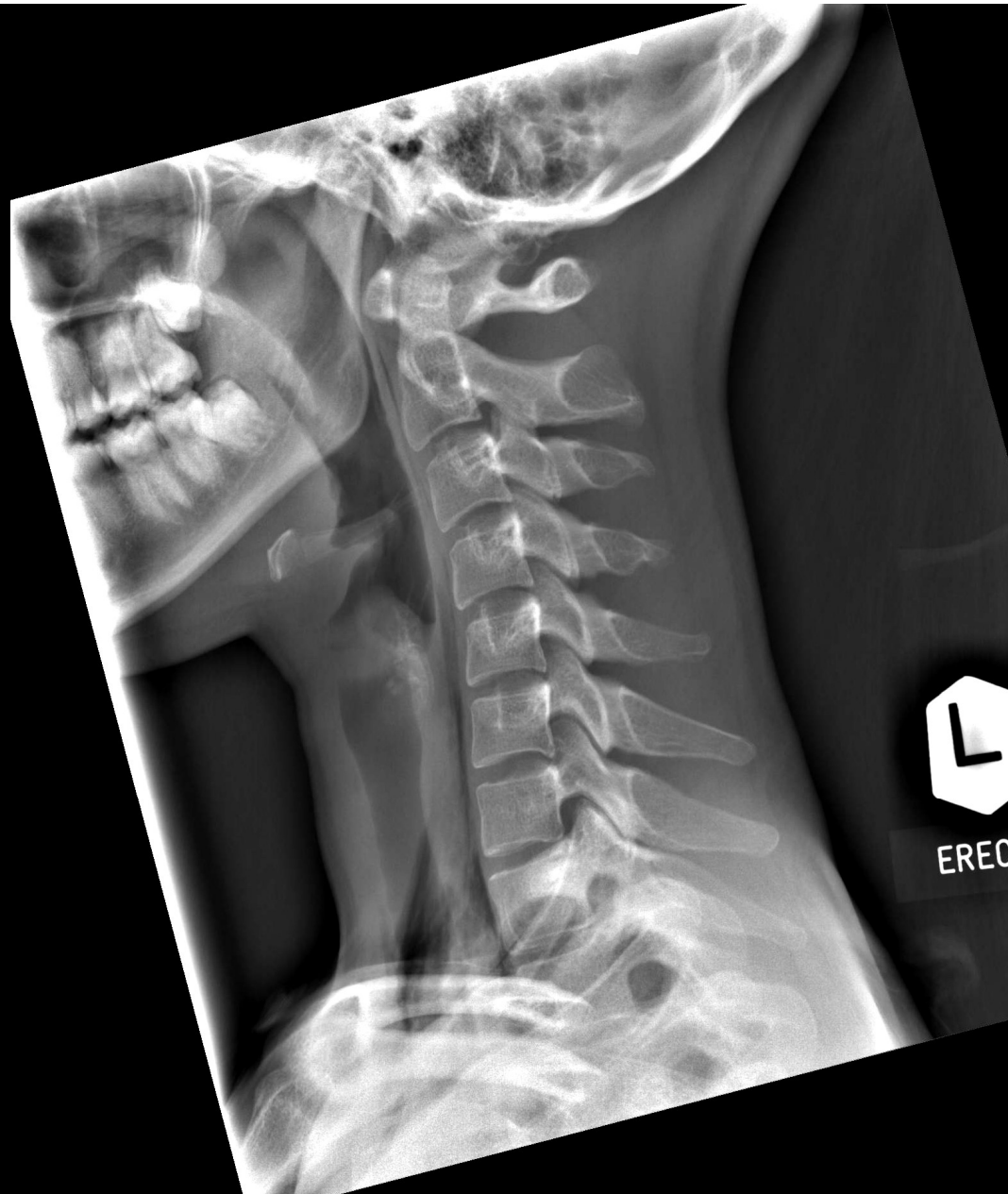July 2017

kwh

Case 1

- F/20, university student
- Non-smoker
- Good past health
- Sudden onset of neck pain, chest pain & SOB during written examination
- BP/P normal
- SpO₂ 98% in room air





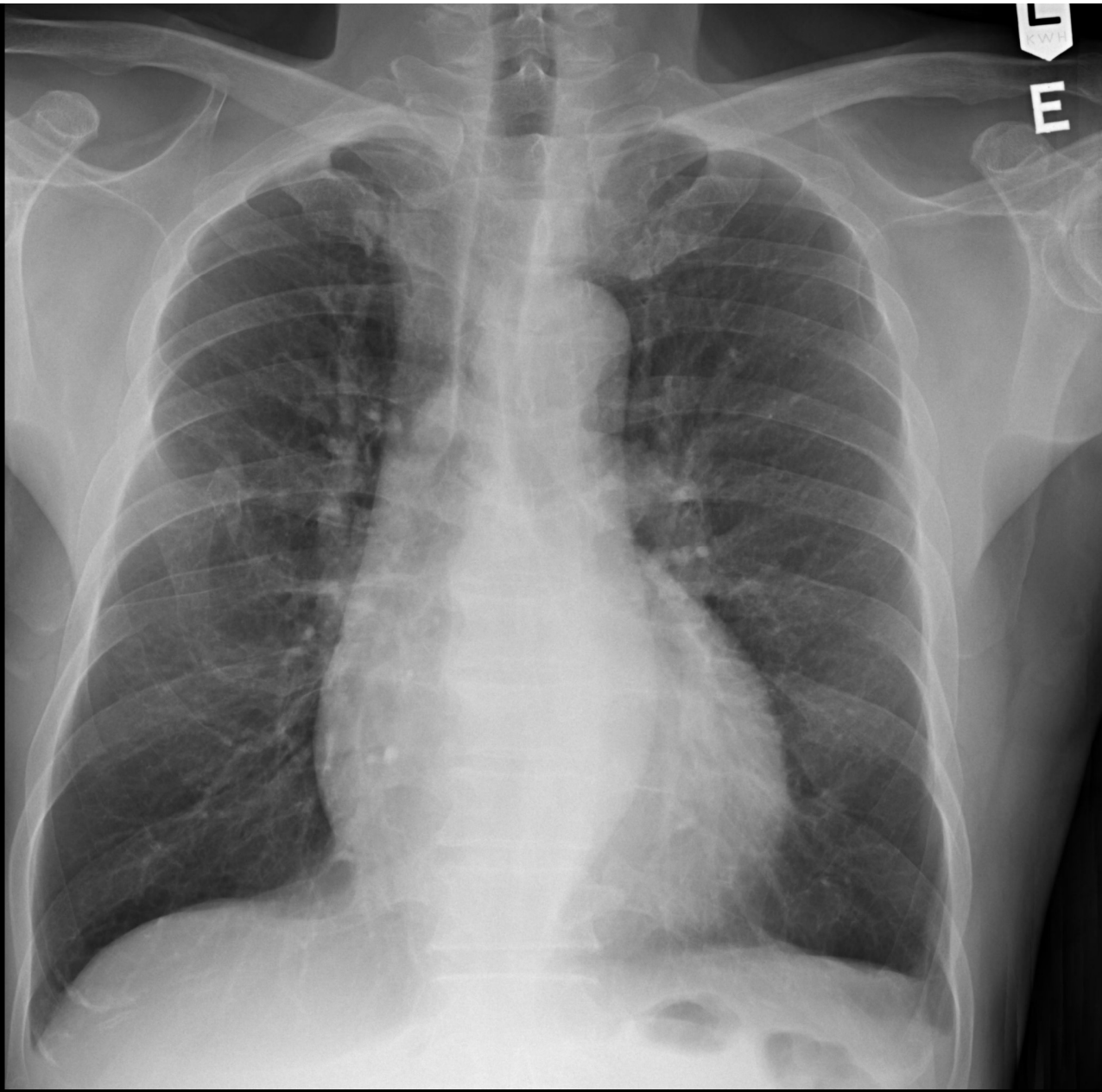
EREC

Questions

- Diagnosis?
- Etiologies?
- Name one eponymous auscultatory sign associated with the condition
- Management?

Case 2

- M/45
- Chronic smoker
- PHx: Graves disease with RAI, on T₄ replacement
- Chest discomfort x 1/12
- SOBOE+

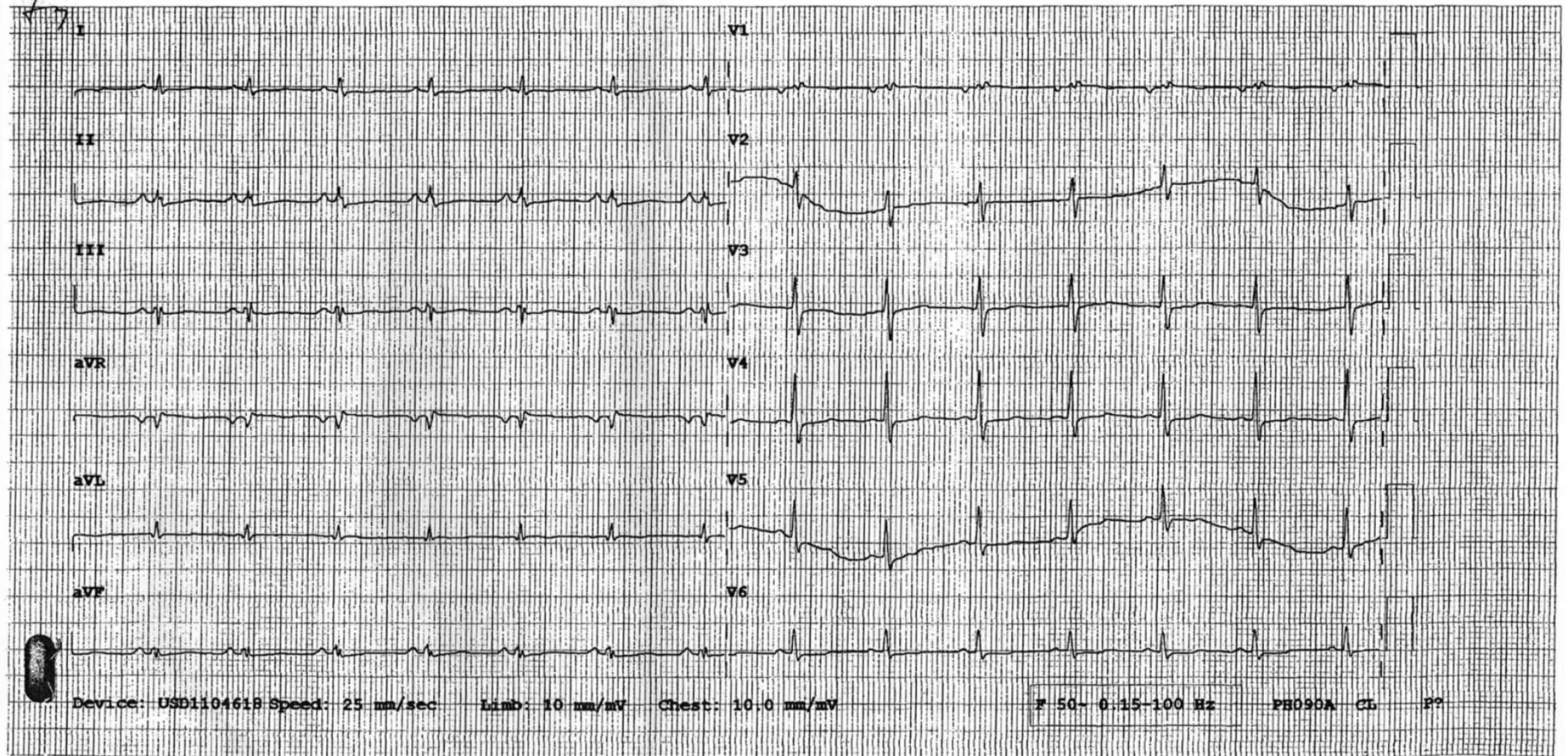


Rate 86 . .
PR 144 . .
QRSD 104 . .
QT 348 . .
QTc 417 . .

--AXIS-- . .
P 69
QRS 69
T 106

12 Lead; Standard Placement

Unconfirmed Diagnosis



Questions

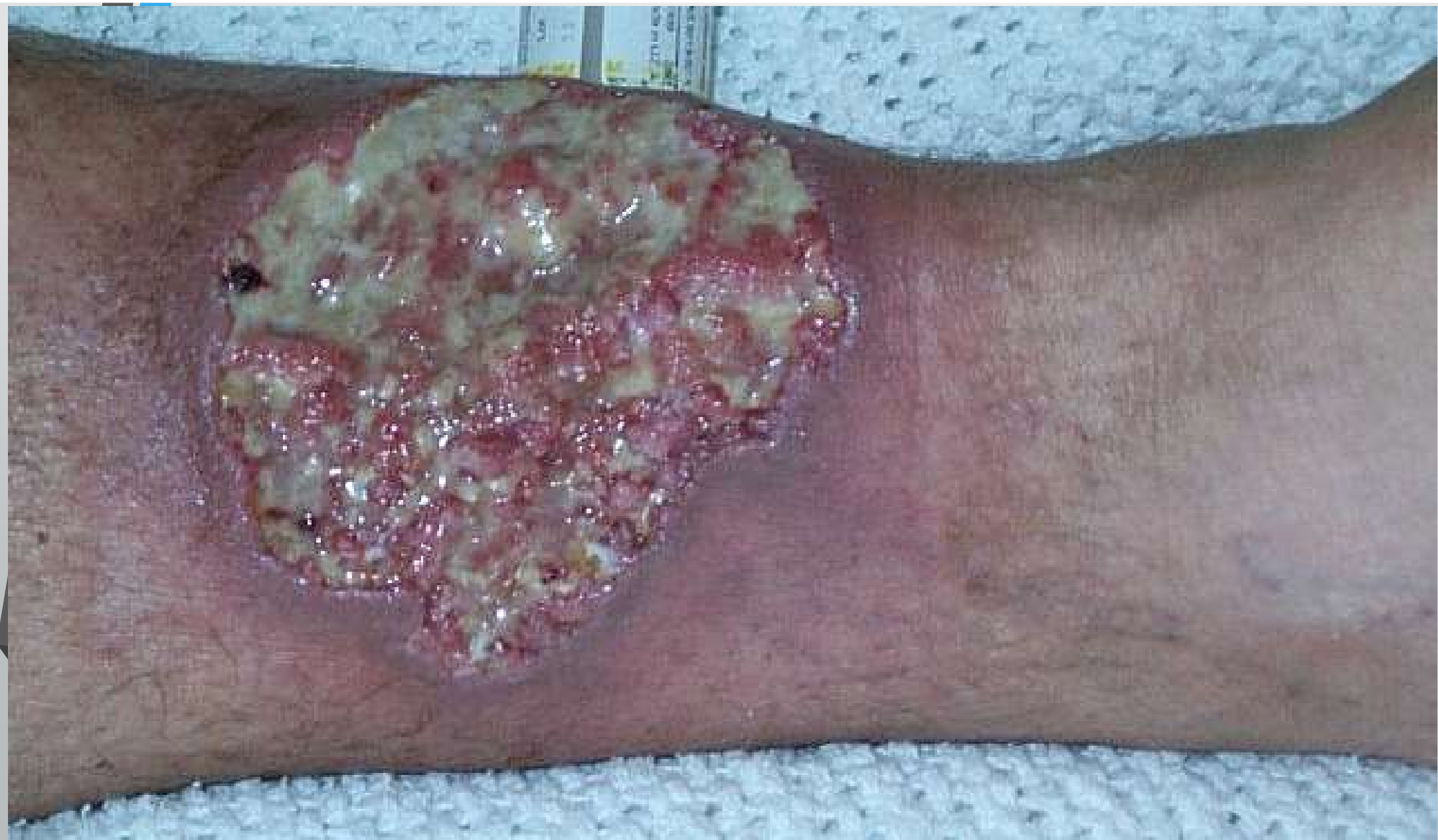- Name the CXR abnormalities
- Name the ECG abnormalities
- Clinical diagnosis?
- What other ECG abnormalities could possibly be present in this condition?
- Name the bedside confirmatory test for the clinical diagnosis?
- How to manage the patient?

Case 3

- M/43
- NSND
- PHx: Crohn's disease FU medical GI
- Left leg lesion x 3/12, started off as small papule
- No trauma history
- Denied drug abuse
- Seen in A&E for several times, wound swab negative x 3 times, not much improved with multiple courses of antibiotics

Case 3

- Physical exam
 - Afebrile
 - Strong peripheral pulses, warm extremities, normal capillary refill
 - Minimal varicose vein
 - Distal sensation normal
 - Clinical picture in next slide

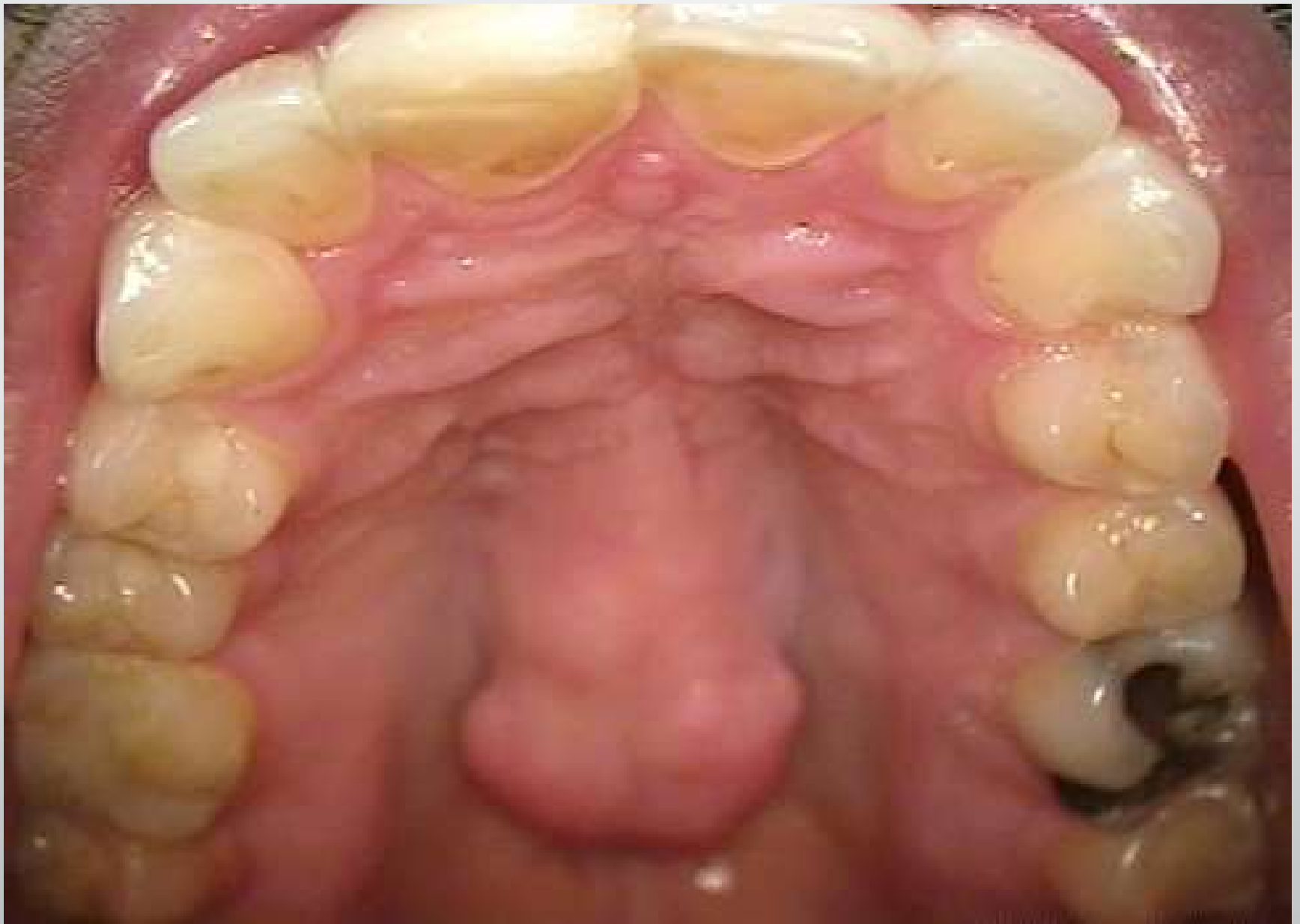

Questions

- Describe the lesion
- Differential diagnoses?
- What is the provisional diagnosis in this patient?
- What is the importance of recognizing this condition?
- Investigations?
- Management?

Case 4

- M/53
- Chronic smoker & chronic drinker
- Cough, RN, sore throat x 3/7
- Seen by GP, referred to A&E for a mass at palate found during throat examination
- P/E
 - Clinical picture in next slide
 - Bony hard
 - Non-tender
 - No contact bleeding

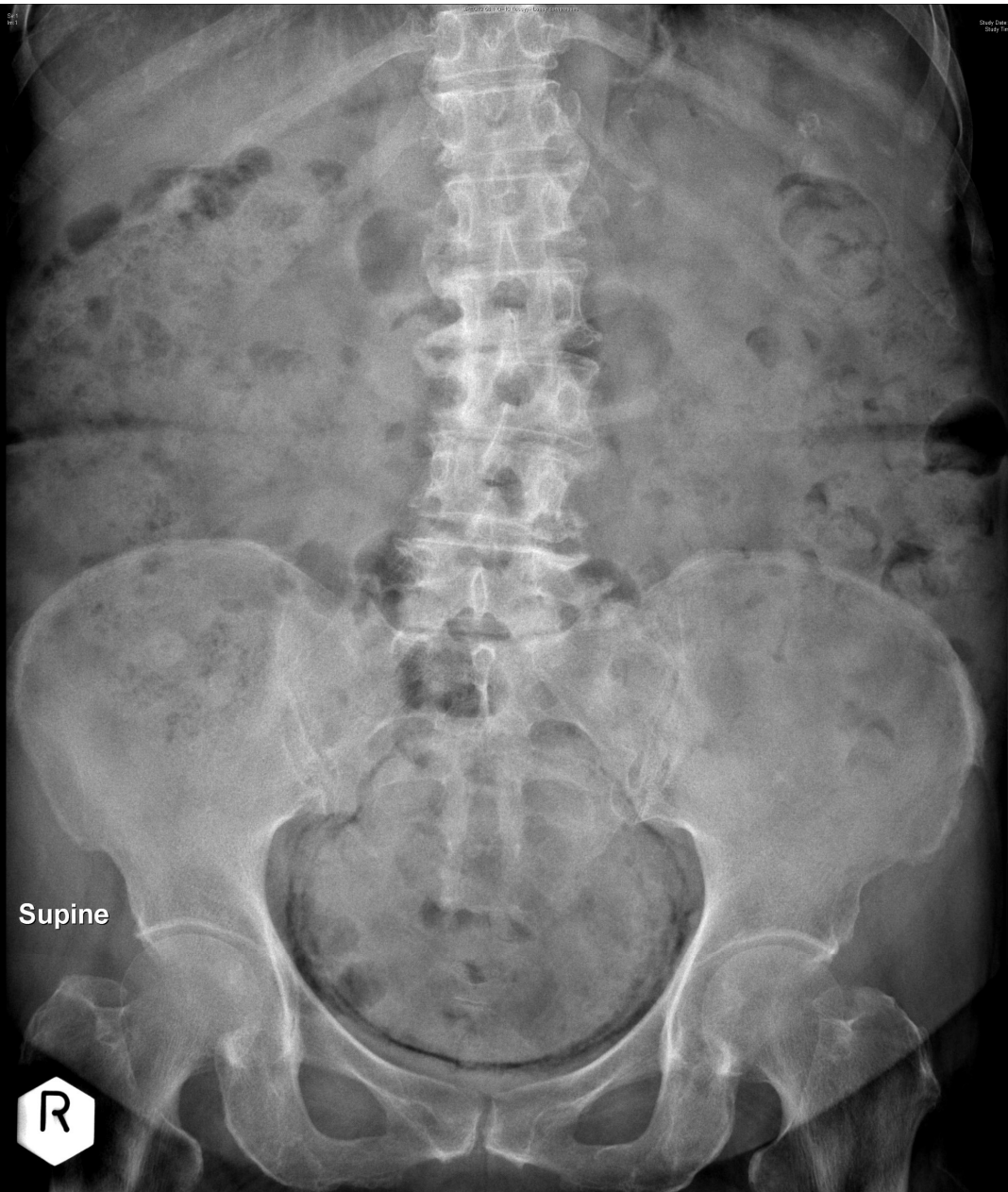

Questions

- What is the clinical diagnosis?
- Indications for referral to specialist?
- Managements?

Case 5

- F/70
- PHx: DM on insulin, HT
- Dysuria, hematuria & urinary frequency x 3/7
- Temp 37.7°C, BP 142/88, P96
- Abdomen soft, slight suprapubic tenderness, no loin tenderness
- Random H'stix: 13.7
- Urine multistix: RBC+++, WBC+++, Nitrite+
- KUB



Supine

R

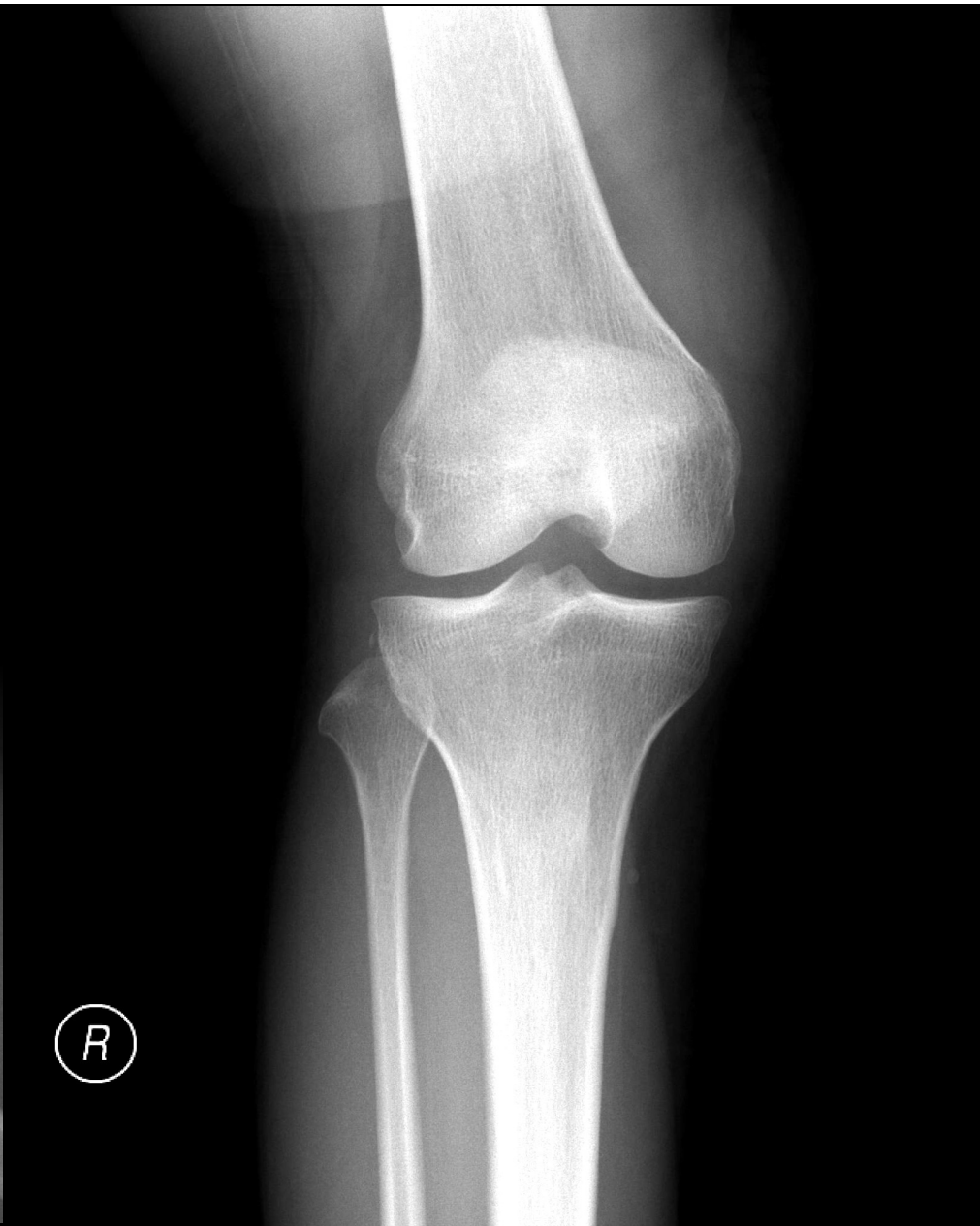
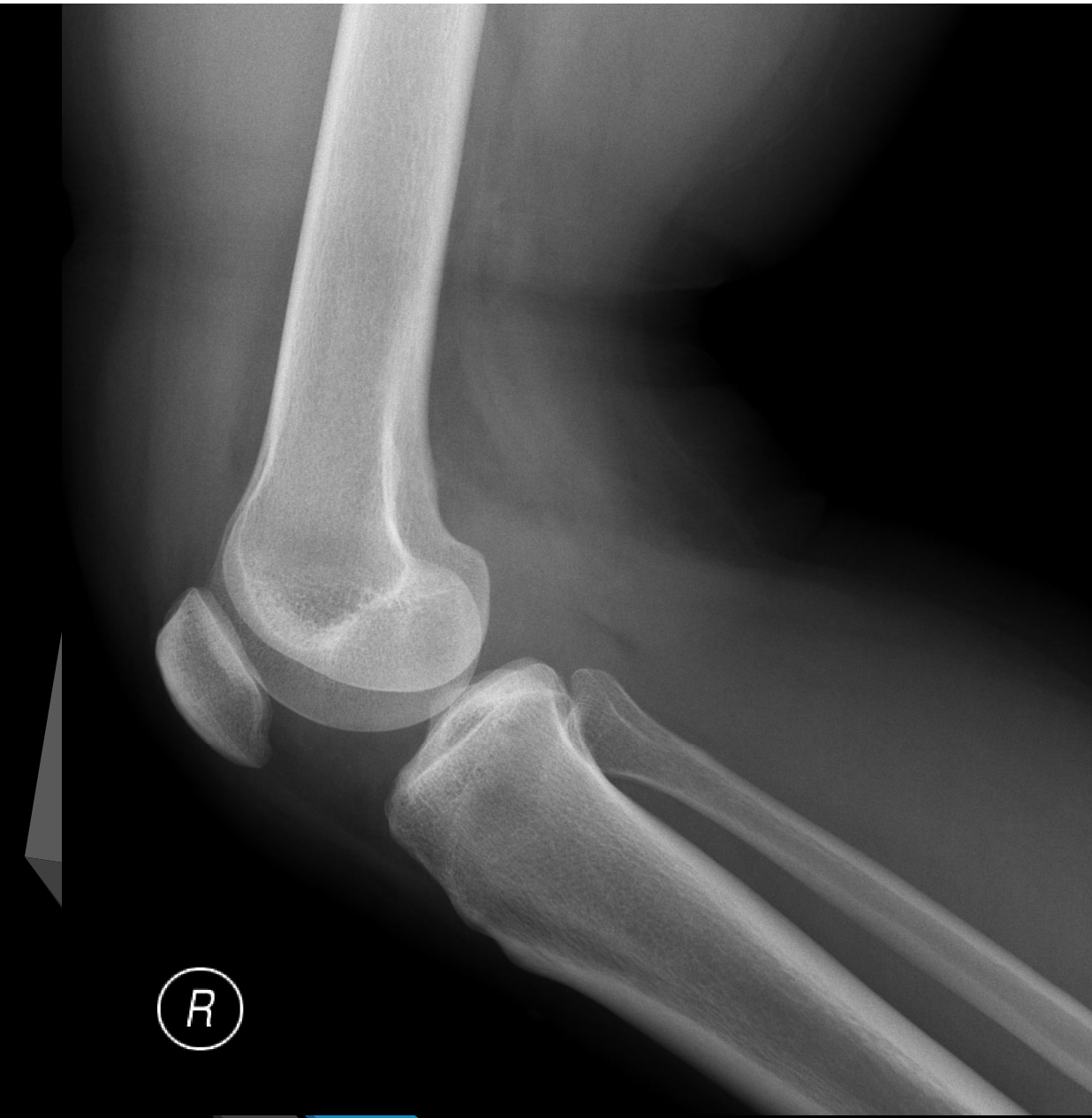Study Date: 27/01/2014
Study Time: 22:28:14
MRN:

Questions

- Diagnosis?
- Frequently associated microorganisms?
- Management?

Case 6

- F/22
- Hip hop dancer
- Fell from upper deck of bed at home 3/7 ago
- Twisted right knee
- Seen by a bonesetter with x-ray taken



Questions

- Diagnosis?
- Important clinical tests for the patient?
- Associated injuries?
- Further investigation?
- A&E management?